Pediatric Forearm Post-Injury Deformity

MARTIN J. HERMAN, MD
PROFESSOR OF ORTHOPEDIC SURGERY AND PEDIATRICS
DREXEL UNIVERSITY COLLEGE OF MEDICINE
ST. CHRISTOPHER'S HOSPITAL FOR CHILDREN
PHILADELPHIA, PA

Closed Reduction and Casting is the Primary Treatment

- 90-95% treated with closed reduction and casting in ED
  - Conscious sedation

Acceptable Reduction Parameters
EXPECT REMODELING

- Proximal radius fractures
- Loss of interosseous space
- Skeletally mature patients

- **Rule of Tens**
  - < 10 year old
    - < 20° angulation
  - > 10 year old
    - < 10° angulation
  - < 30° malrotation
  - Bayonet apposition
    - 2 years growth remaining

Malunion of the Forearm

- Loss of rotation
  - Functional issues
- Poor cosmesis
  - “Crooked arm”

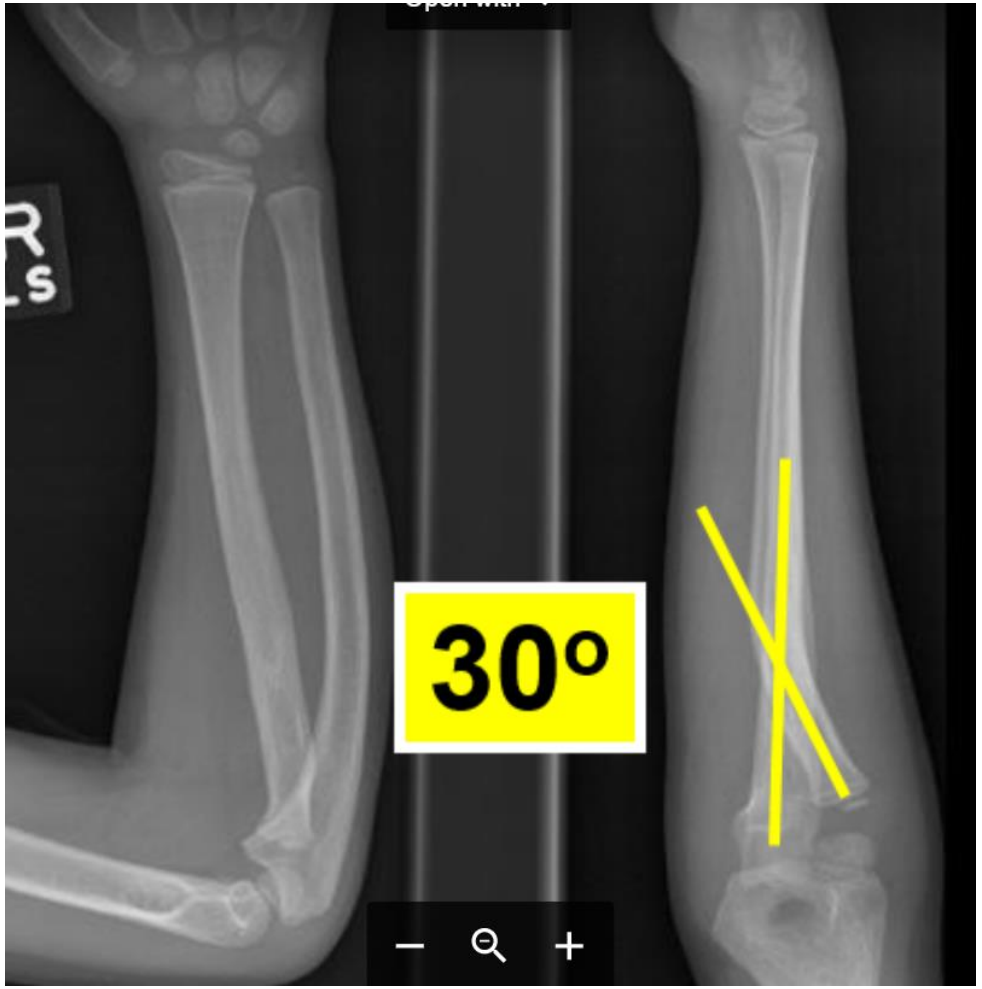

Correction of Malunion
Less than 6 weeks from Injury

- Wedge cast
- Repeat manipulation
- Deformity correction and fixation
  - Closed osteoclasis
  - Open osteotomy

2 weeks after injury

4 weeks after injury

Osteoclasis and Fixation

- Mini-open reduction of radius
  - IM nail fixation
- Closed osteoclasis of ulna
- Long arm cast

Correction of Malunion
More than 6 weeks after Injury

Osteotomy for Malunited Forearm Shaft Fractures in Children

JPO, 2006

Charles T. Price, MD and D. Raymond Knapp, MD

- Angulation > 30°
  - Immediate osteotomy
- Angulation 20-30°
  - Observe remodeling for 6 m

Best Outcomes of Osteotomy

Review Article

JHS(E)

Factors determining outcome of corrective osteotomy for malunited paediatric forearm fractures: a systematic review and meta-analysis

K. C. Roth[1,3], M. M. J. Walenkamp[2], R. C. I. van Geenen[3], M. Reijman[1], J. A. N. Verhaar[1] and J. W. Colaris[1]

The Journal of Hand Surgery (European Volume) 2017, Vol. 42E(8) 810–816
© The Author(s) 2017

Reprints and permissions:
sagepub.co.uk/journalsPermissions.nav
DOI: 10.1177/1753193417711684
journals.sagepub.com/home/jhs
SAGE

- Surgery < 1 year from injury
- Angulation > 20°
- Use of 3-D CT for pre-operative planning

Planning for Surgery
Normal Anatomy

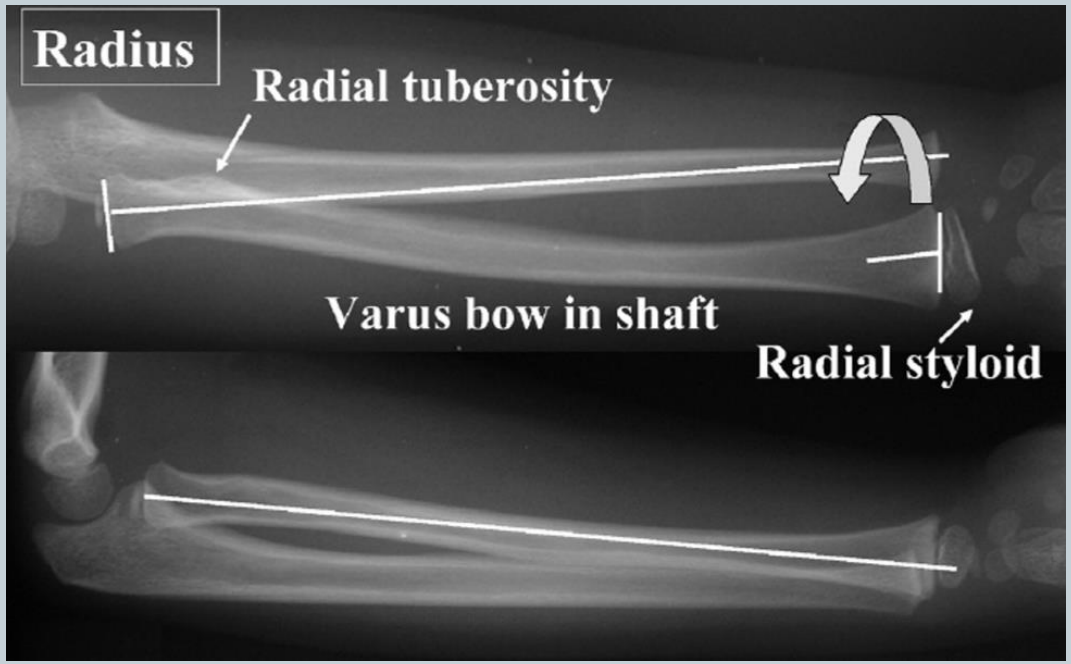

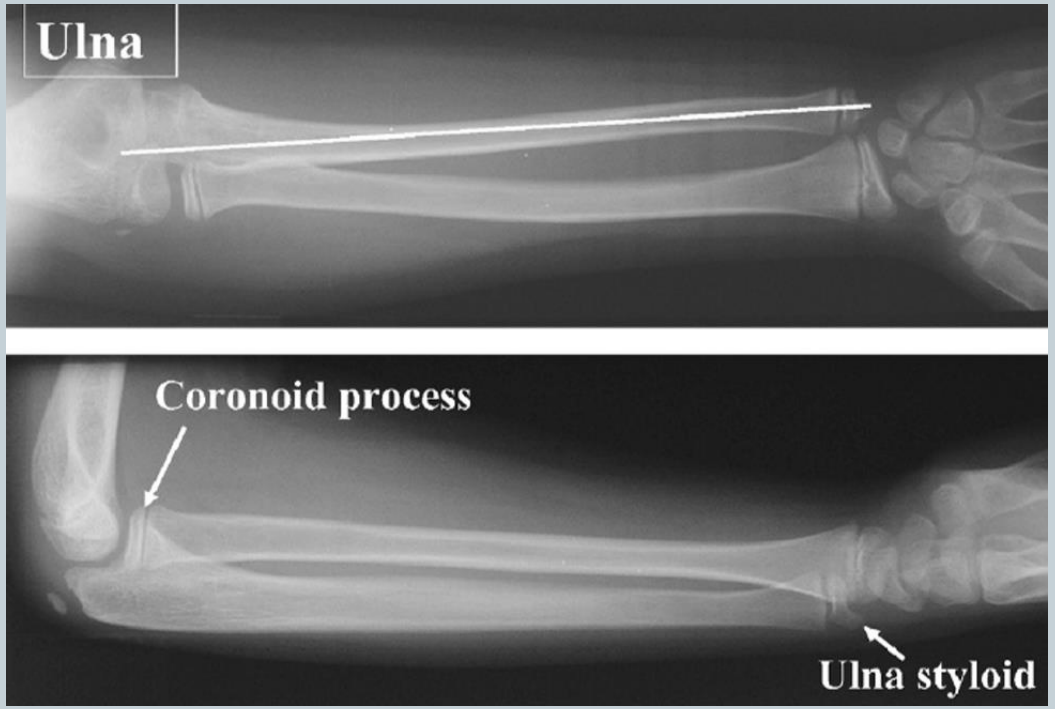

Closing Wedge Osteotomies
Address Angulation and Rotation

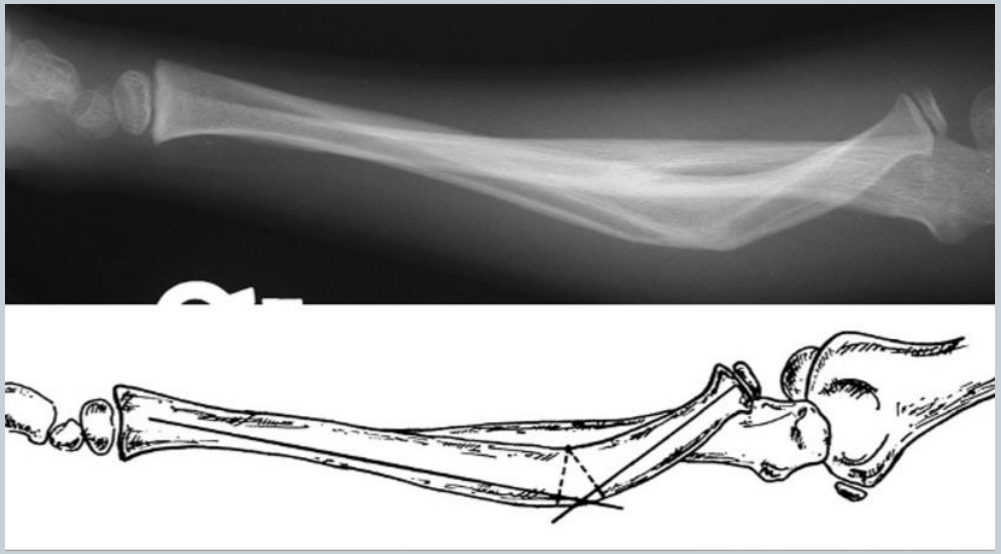

Fixation

Radius: Henry approach
Ulna: Ulnar approach

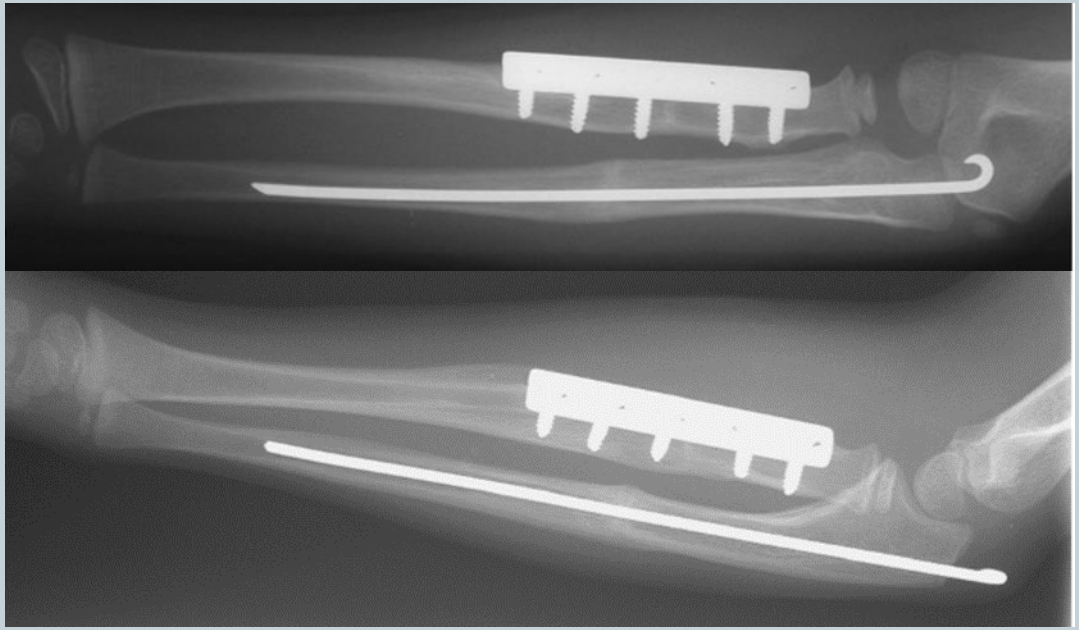

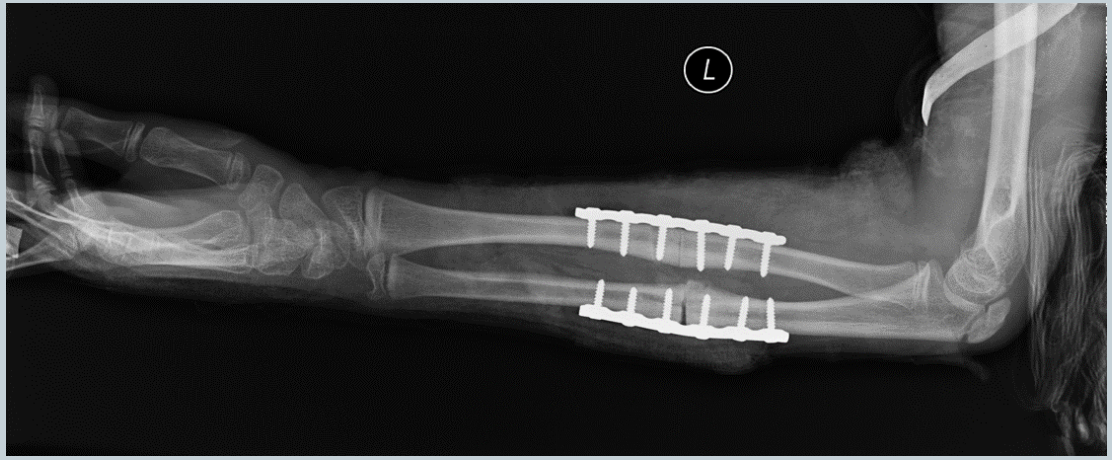

2.7 mm compression plates

Preoperative 3D Modeling

Computer-Assisted Corrective Osteotomy for Malunited Diaphyseal Forearm Fractures

Junichi Miyake, MD, Tsuyoshi Murase, MD, PhD, Kunihiro Oka, MD, PhD, Hisao Moritomo, MD, PhD, Kazuomi Sugamoto, MD, PhD, and Hideki Yoshikawa, MD, PhD

JBJS 2012 *Investigation performed at Osaka University Graduate School of Medicine, Osaka, Japan*

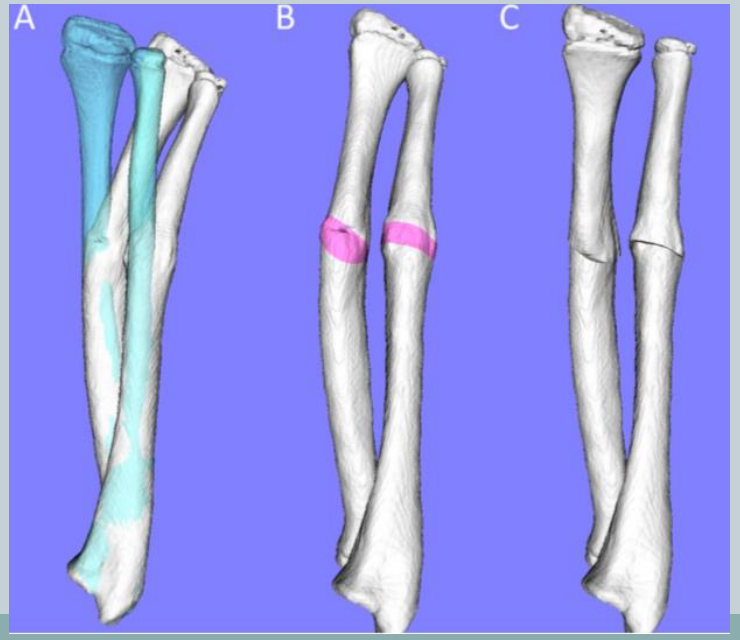

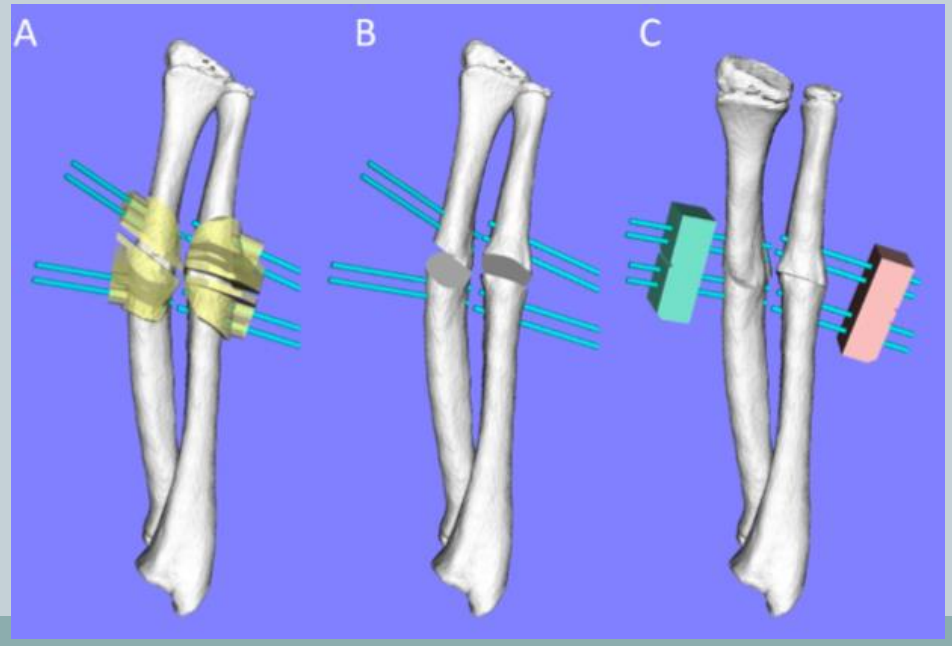

Pre-manufactured Cutting Jig

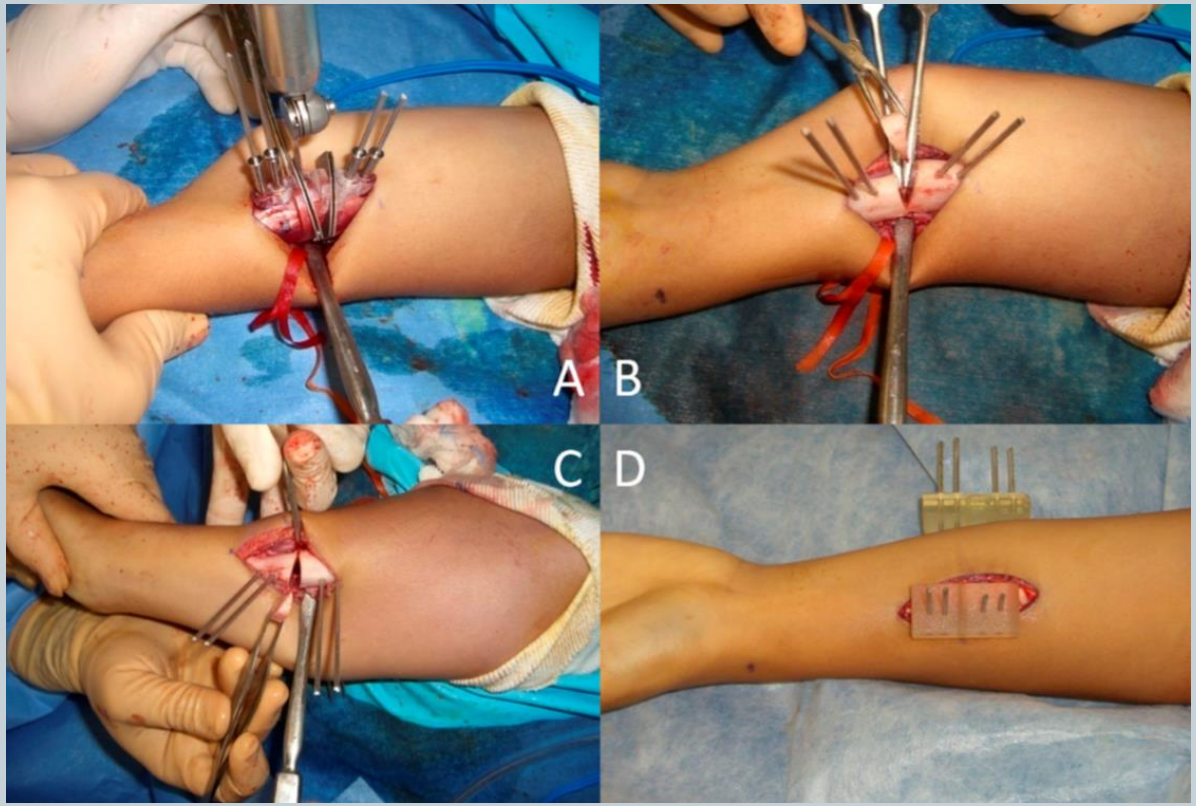

Summary

- Remodeling of forearm fractures has limits
- Malunion leads to poor outcomes
  - Loss of pronation/supination
- Osteotomy yields best results
  - When performed early for > 20° of angulation
- Preoperative planning and surgery must be executed well

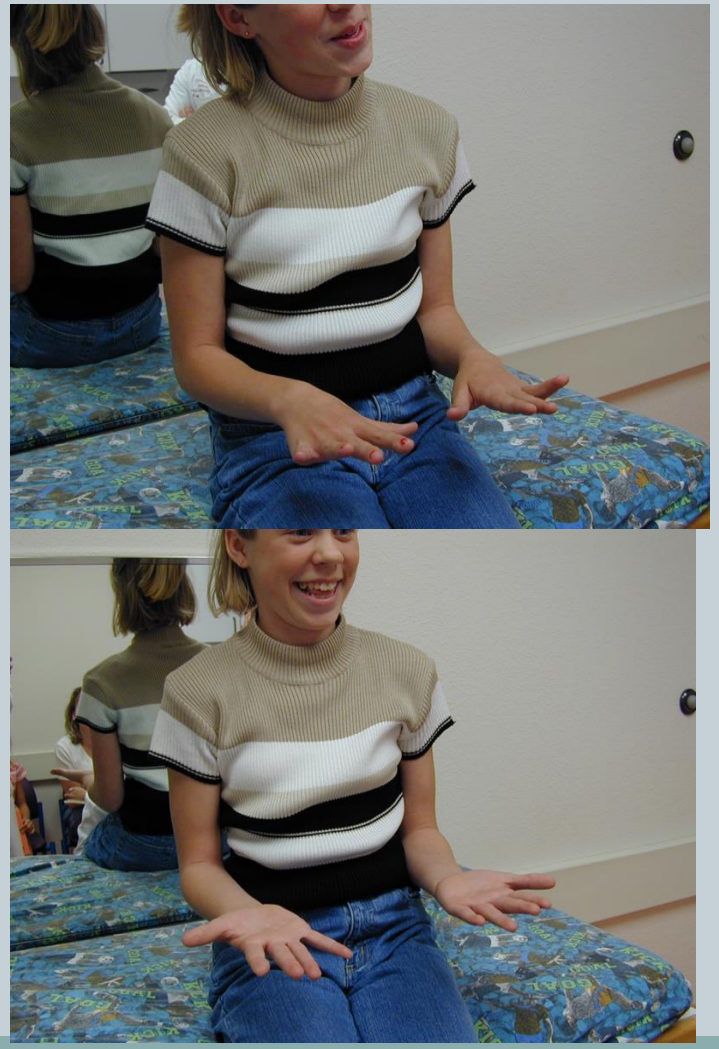

Thanks to Scott Kozin